



ALLIANCE™

[.https://gsa.rakadev.com](https://gsa.rakadev.com)**Responsible
Seafood**
ADVOCATEHealth &
Welfare

Southern brown shrimp found susceptible to IMNV

1 January 2007

By Renato Pinheiro Gouveia , Maria de Lourdes Freitas and Dr. Leonardo Galli

Disease marked by opacity in the abdominal muscles and necrosis of the tails

In September 2002, unusual mortality in farmed Pacific white shrimp (*Litopenaeus vannamei*) was reported at a shrimp farm in the state of Piauí in northeastern Brazil. Affected animals were lethargic and presented opacity in the second or third abdominal segments. Persistent, low-level mortalities reduced the affected population by 50-70 percent.

Some animals presented reddish coloration in the last abdominal segment and totally necrotic tails. Histopathological analyses showed numerous spheroids in their lymphoid organs and muscular necrosis with hemocytic infiltration. Some specimens presented necrotic lesions in the hepatopancreas.



Shrimp with IMN have reddish areas on their muscle and tail areas.

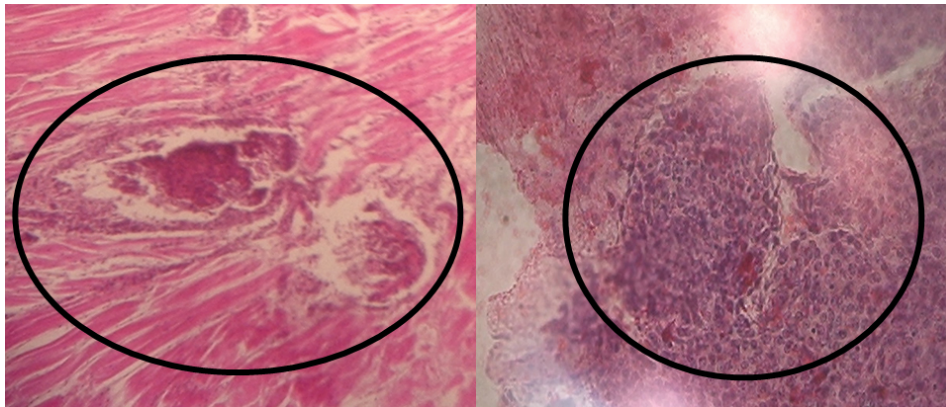
Infectious myonecrosis virus

Infectious Myonecrosis Virus (IMNV) has since been identified as the causative agent of the necrosis in *L. vannamei*. Until now, the disease was reported as naturally occurring in cultured *L. vannamei*. The nonenveloped virus was also experimentally induced in Pacific blue shrimp, *L. stylirostris*; and black tiger shrimp (*Penaeus monodon*).

Southern brown shrimp infection

To overcome mortalities produced by IMNV in cultured *L. vannamei* and increase production, some Brazilian shrimp farmers are testing the southern brown shrimp (*Fenneropenaeus subtilis*) in grow-out ponds.

In a recent test at a commercial farm, two 2-ha ponds were stocked with southern brown shrimp at 10 postlarvae per square meter. The animals were fed a 35 percent-crude protein commercial diet formulated for *L. vannamei*. Dissolved-oxygen levels remained 5-8 ppm during the whole cycle. After 65 days of culture, the first symptoms of IMNV were noticed in animals in both ponds. At this time, the shrimp averaged 7 grams in body weight. At harvest, body weights averaged 11 grams, and the survival rates in the ponds were 23 and 26 percent.



Testing of affected brown shrimp showed spheroid formation in the lymphoid organ and necrosis of the muscle tissue.

Diseased shrimp presented the characteristic opacity in the abdominal muscles and necrosis of the tails. Histopathological sections stained with the salts hematoxylin and eosin showed spheroids in the lymphoid organs and focal necrosis in muscle, with hemocytic infiltration.

To confirm the diagnosis, reverse transcription polymerase chain reaction (RT-PCR) testing was done using RNA extracted from the gills and pleopods of affected shrimp with a commercial kit for IMNV and primers designed at the University of Arizona. Results confirmed the presence of IMNV in the cultured *F. subtilis*, and thus expanded the host range susceptibility of IMNV.

(Editor's Note: This article was originally published in the January/February 2007 print edition of the Global Aquaculture Advocate.)

Authors



RENATO PINHEIRO GOUVEIA

Centro de Diagnostico de Doenças de Camarão
UnP Campus Salgado Filho
Lagoa Nova, Natal/RN, Brazil



MARIA DE LOURDES FREITAS

Centro de Diagnostico de Doenças de Camarão
UnP Campus Salgado Filho
Lagoa Nova, Natal/RN, Brazil



DR. LEONARDO GALLI

Instituto de Investigaciones Pesqueras
Facultad de Veterinaria, UDELAR
Tomás Basáñez 1160, CEP: 11300
Montevideo, Uruguay

gallimat@gmail.com (<mailto:gallimat@gmail.com>)

Copyright © 2023 Global Seafood Alliance

All rights reserved.